



Radiofrequency-assisted Liposuction for Arm Contouring: Technique under Local Anesthesia

Spero Theodorou, MD
Christopher Chia, MD

Background: Contouring of the arms that does not involve skin excision remains a difficult challenge due to the dependent nature and quality of the skin. Although brachioplasty remains effective, it requires a lengthy incision. Radiofrequency-assisted liposuction (RFAL) may improve skin retraction with a satisfactory aesthetic result without skin resection and the resultant scar. The purpose of this study is to present our experience of RFAL arm contouring under local anesthesia, detailing safety guidelines, the marking technique, operative technique, complications, third-party surgeon appraisal, and patient satisfaction survey.

Methods: Forty patients underwent RFAL under local tumescent anesthesia for aesthetic arm contouring. Postoperative patient satisfaction surveys were conducted and independent third-party surgeons were surveyed to assess improvements in contour and skin quality with preoperative and postoperative photographs.

Results: Complications included 1 burn near the elbow treated successfully with local wound care and 1 seroma that resolved with aspiration. The patient survey indicated that most patients had minimal or no discomfort with the injection of local anesthesia, application of radiofrequency energy, or aspiration of fat. The majority of patients were satisfied with their contouring result and degree of skin tightening. Third-party plastic surgeons found the improvement in contouring and degree of skin tightening good to excellent.

Conclusions: In appropriately selected patients, RFAL arm contouring under local anesthesia represents an alternative procedure with acceptably low morbidity and high patient satisfaction. To achieve consistent results while minimizing complications, consideration to anatomic details, infiltration of the local anesthetic, and application of the radiofrequency energy must be given. (*Plast Reconstr Surg Glob Open* 2013;1:e37; doi:10.1097/GOX.0b013e3182a58c80; Published online 29 August 2013.)

Reducing and aesthetic contouring of the arms without excising skin present a difficult challenge.¹ This is due to the dependent nature of the redundant skin and its relative non-

adherence to the underlying structures following suction-assisted lipectomy (SAL). Understanding the concept of adherence is helpful in minimizing contour deformities in SAL.² Although brachioplasty remains an effective procedure for patients with massive weight loss and severe skin laxity, it requires a lengthy incision and may be associated with other significant morbidities.³ Some have

From the BodySculpt Corporation, New York, N.Y.

Received for publication June 12, 2013; accepted June 18, 2013.

Copyright © 2013 American Society of Plastic Surgeons. Unauthorized reproduction of this article is prohibited. This is an open-access article distributed under the terms of the Creative Commons Attribution-NonCommercial-NoDerivatives 3.0 License, where it is permissible to download and share the work provided it is properly cited. The work cannot be changed in any way or used commercially.

DOI: 10.1097/GOX.0b013e3182a58c80

Disclosure: *The authors are consultants for Invasix Corporation. No outside funds were used in the cases presented or in the preparation of this article except for patient remuneration according to IRB protocol provided by Invasix Corporation. The Article Processing Charge was paid for by the authors.*

found good skin retraction with aggressive SAL of all layers of the arm.^{4,5} It is postulated that energy-assisted liposuction may improve skin retraction⁶ and the overall aesthetic result in nonexcisional upper extremity contouring procedures. For ex-

ample, increased retraction was observed in the inferior portion of the arm skin in patients treated with ultrasonic-assisted liposuction.⁷ Radiofrequency-assisted liposuction (RFAL) is a new technique that utilizes electromagnetic energy applied to the

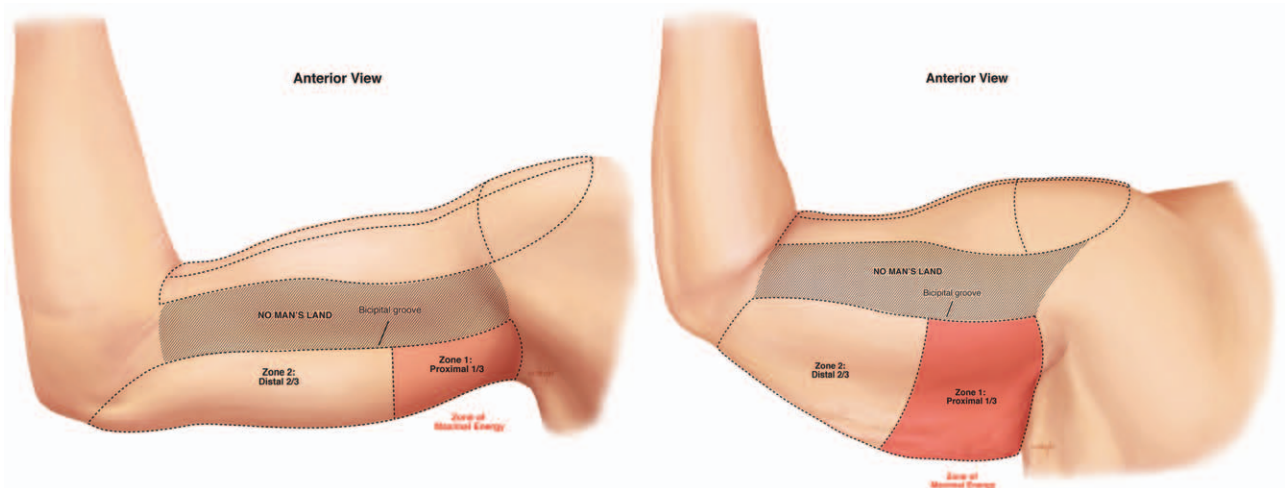


Fig. 1. Depiction of zones 1 and 2 and “No Man’s Land,” anterior view, of a normal (A) and overweight (B) patient.

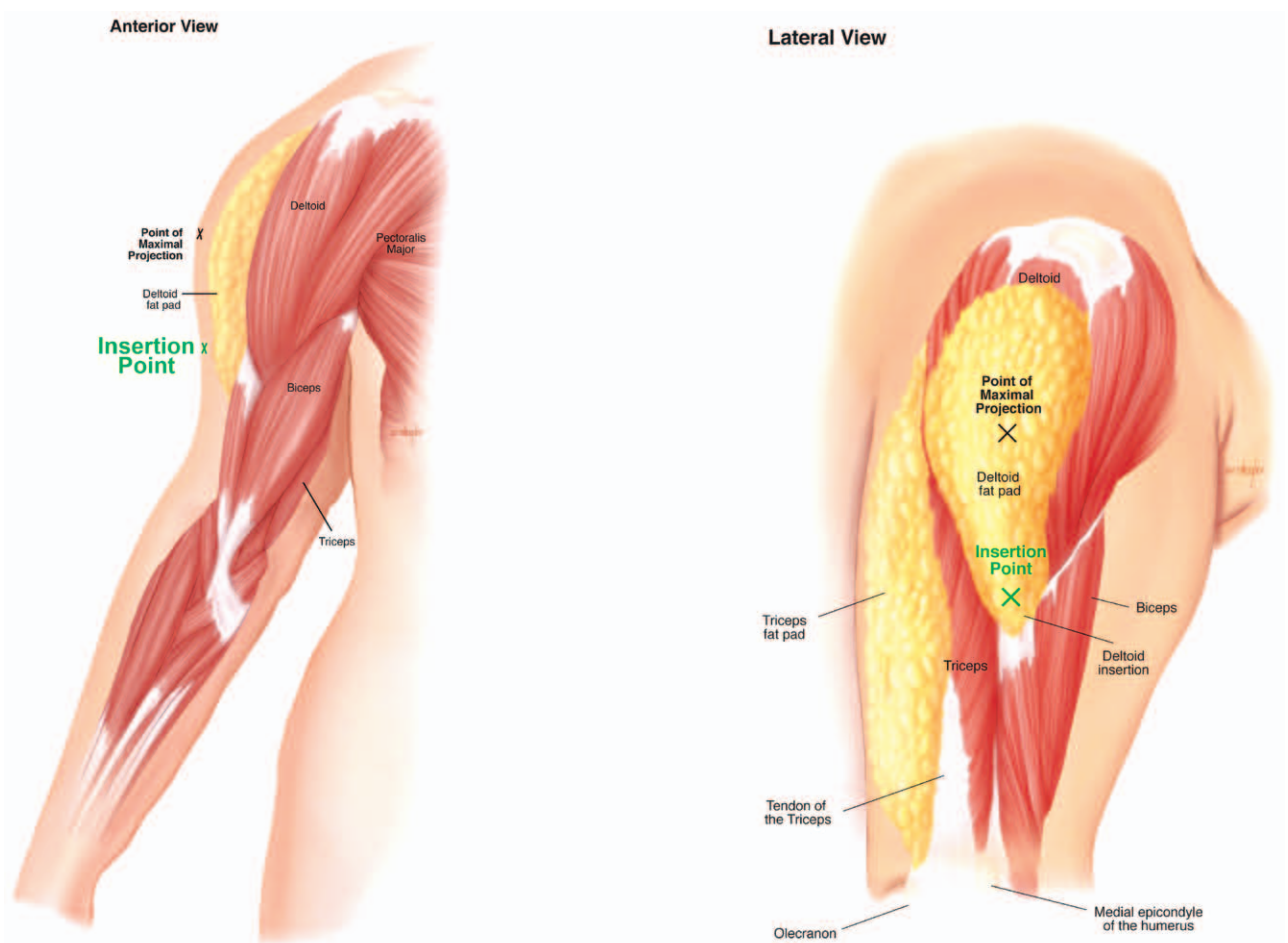


Fig. 2. Anterior and lateral views of the deltoid fat pad with the point of maximal projection and insertion point identified.

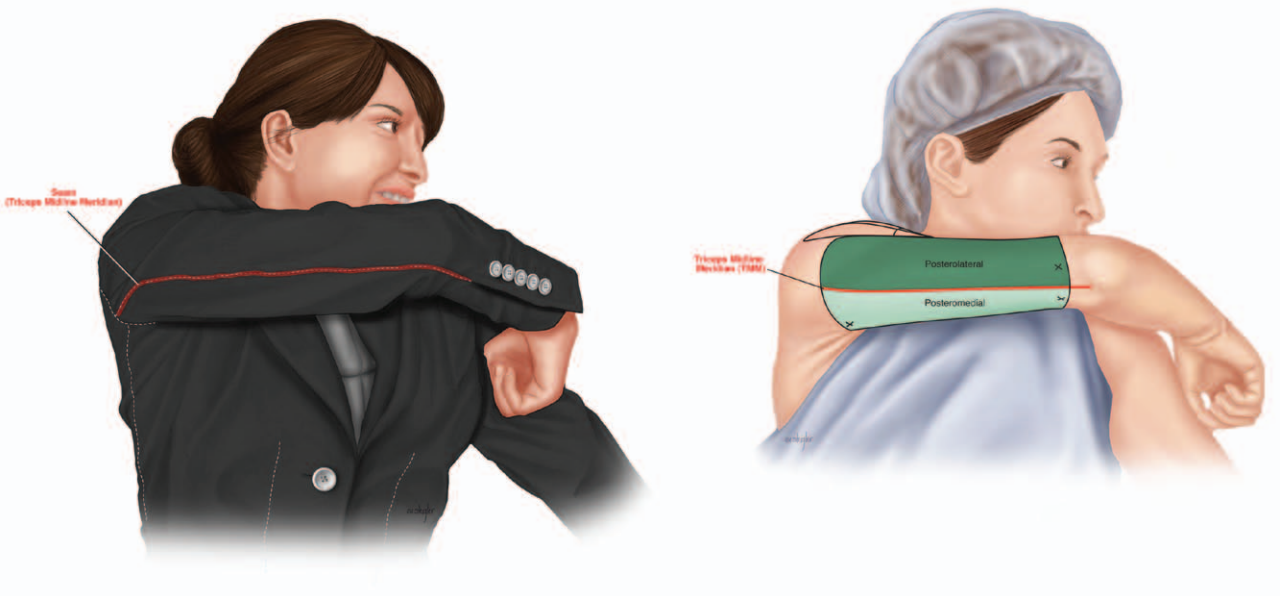

Fig. 3. TMM representing the area (“seam”) of maximal heat application and contraction.

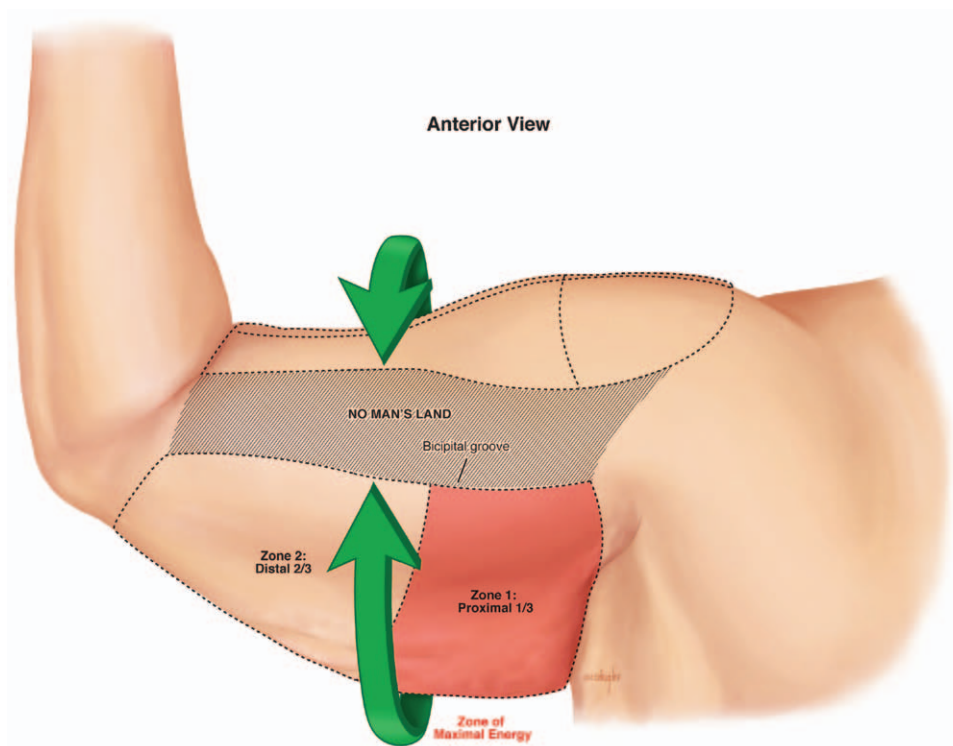


Fig. 4. Schematic representation of the 270° release of soft tissues.

soft tissues in a bipolar manner to stimulate contraction and collagen formation.^{6,8} The purpose of this study is to present our experience of RFAL arm contouring under local anesthesia, detailing safety guidelines, marking technique, operative technique, complications, third-party surgeon appraisal, and patient satisfaction survey.

MATERIALS AND METHODS

Forty patients underwent RFAL of bilateral arms under local anesthesia from April 2009 through February 2012 in an accredited (American Association for Accreditation of Ambulatory Facilities) operating room. Patients were recruited as volunteers from existing patient and staff referrals. Those who were

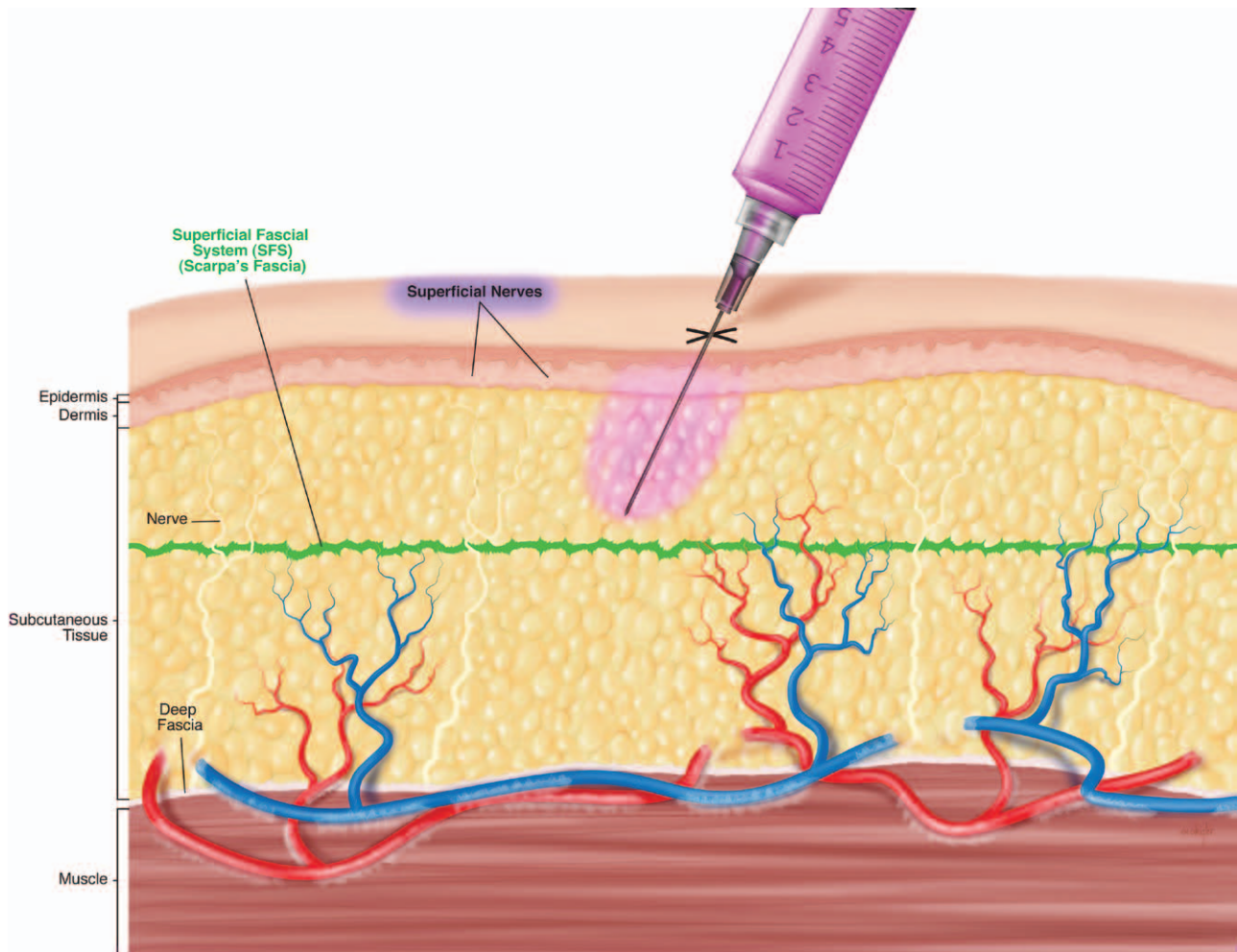


Fig. 5. Step 1: Initial deep injection of local anesthetic (1% lidocaine with 1:100,000 epinephrine) for access site analgesia before developing the skin wheal (see text).

accepted into the study and underwent the procedure had remuneration in the amount of \$175 if they had completed the follow-up appointment protocol (3 visits minimum). One man and 39 women ranged in age from 25 to 64 years with a mean of 40 years. No patient had a body mass index over 35. Skin types ranged from Fitzpatrick type 1 to 4. All RFAL procedures were conducted in compliance with an Institutional Review Board protocol (Essex Institutional Review Board, Lebanon, NJ) utilizing the BodyTite RFAL platform (Invasix, Yokneam, Israel). The device is pending Food and Drug Administration approval in the United States. Exclusion criteria included history of cancer, liver or kidney disease, refractory herpes, presence of a pacemaker/defibrillator, blood clotting disorder, pregnancy, and Fitzpatrick VI skin types.

Following a history and physical examination, a focused arm examination begins with the patient in the standing position with her arms on the side and

palms placed against the lateral thighs. This is an optimal position to assess the triceps region and lateral projection of the deltoid fat pad (DFP). The arm is then positioned with the elbow flexed at 90° (Fig. 1, “bat wing position”) to allow visual and tactile assessment of the soft tissue inferior to the bicipital groove. The dependent portion of the arm is further subdivided into the proximal one-third or “zone 1” and the distal two-thirds or “zone 2” (Fig. 1). In our experience, most fat and skin laxity was found in zone 1 and typically required a greater amount of energy. Next, the area between the medial border of the DFP and the bicipital groove is marked as “No Man’s Land” (Fig. 1) where no treatment is performed because of the increased risk of contour deformities where the skin is thinner and because of its proximity to neurovascular structures.

The quality of the skin of the arms is then evaluated where the presence of striae, dermal thickness, subcutaneous fat, and Fitzpatrick skin type

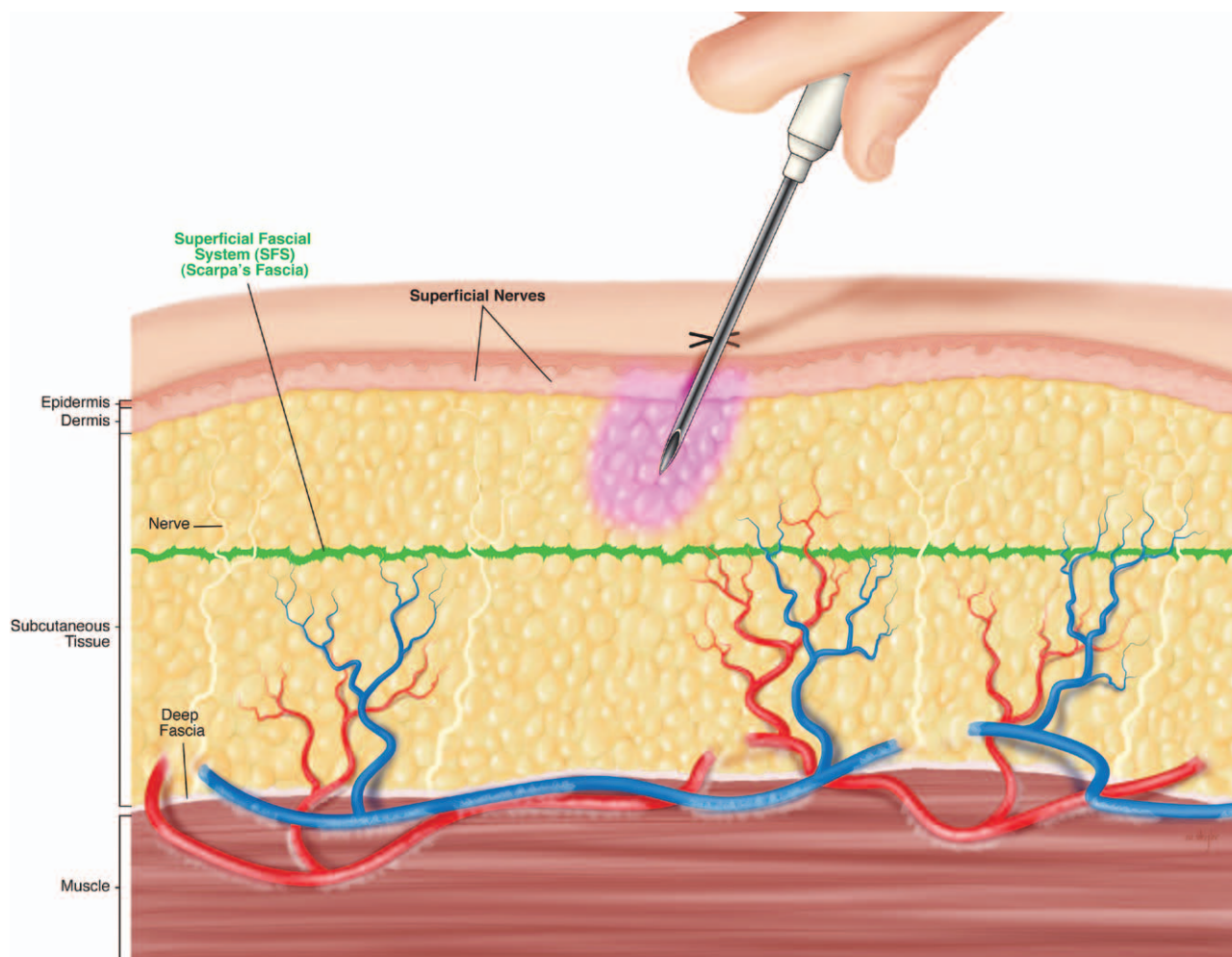


Fig. 6. Step 2: Access incision is developed by puncturing the skin with a 14-gauge needle, resulting in a circular opening.

are noted. Patients are cautioned that the presence of dermal striae may affect the overall aesthetic result by limiting the contractile nature of the dermis and compromising the redraping of the skin envelope. Dermal thickness and the quantity of underlying soft tissue structures affect the potential for skin contraction with RFAL.⁶ We have found that the thicker the dermis, the greater the degree of contraction. Radiofrequency-mediated septo-fascial contraction requires an adequate adipose layer and underlying matrix in order for it to be effective.⁶ In our experience, skin quality and laxity are the most important determinants in candidate selection where those with loose skin combined with a fat layer of less than 10 mm had a higher risk of irregularities.

Technique

Patients are given 10 mg diazepam, 500 mg cephalexin, and 5/325 mg of hydrocodone/acetaminophen orally 1 hour before surgery. With the arm

flexed at 90°, the bicipital groove, “No Man’s Land,” and zones 1 and 2 are marked.

DFP Marking

The DFP is a distinct and measurable anatomic region that has both medical⁹ and aesthetic ramifications. A longitudinal line is drawn along the length of the arm starting at the acromion of the scapula intersecting the deltoid insertion. A transverse line is drawn at the point of maximal projection of the DFP. We initially used this as an entry point for liposuction of the DFP, but with experience, we moved to a more distal point on the same longitudinal line approximately 3 cm superior to the insertion point of the deltoid (Fig. 2). We believe that the natural depression between the deltoid and biceps conceals the entry scar.

Triceps Fat Pad Marking. The Triceps Midline Meridian (TMM) (Fig. 3) is defined as the longitudinal line dividing the triceps fat pad area into medial and lateral treatment zones. A greater amount of energy is

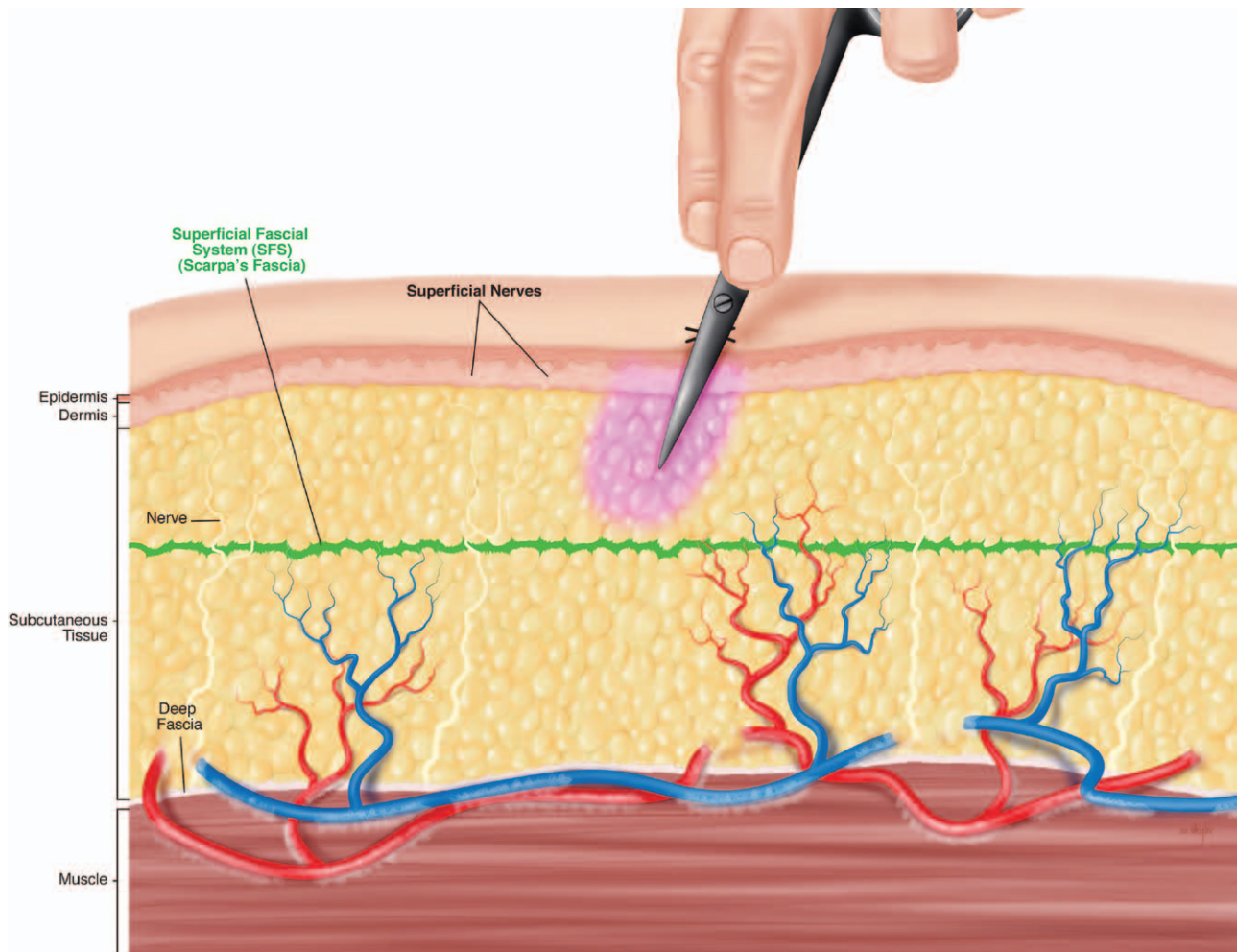


Fig. 7. Step 3: The access incision/puncture site is dilated as needed with a tenotomy scissors to accommodate a variety of cannulas.

applied to the TMM to facilitate contraction and tissue recruitment toward this line. In our opinion, this serves as an internal seam analogous to a tailor's seam on a suit. Following the application of the radiofrequency (RF) energy, we perform 270° SAL to accomplish 2 objectives: The first is to debulk and reduce the overall circumference of the arm, and the second is a 270° discontinuous partial release of the soft tissue envelope that allows for better redraping of the skin (Fig. 4). As noted above, by applying a larger amount of heat to the TMM, a controlled thermal injury translates into radial contraction to serve as a point for recruitment of the released soft tissue. Incision points are marked approximately 2–3 cm lateral and medial from the TMM at the elbow, with a third incision marked at the junction of the arm and the axilla.

Procedure

Local Anesthetic/Tumescent Infiltration Technique. Once marked, the patient is placed in the supine position.

The arm is circumferentially prepped and draped in standard sterile fashion. A 30-gauge needle is passed through the dermis without injecting until the tip is in the subcutaneous space (Fig. 5). Next, anesthetic is injected as the needle is withdrawn slowly with the last step being the creation of the intradermal wheal to minimize pain. The skin is then punctured with a 14-gauge needle (Fig. 6). In our opinion, a circular puncture is less likely to enlarge along the relaxed skin-tension lines than a linear incision and heals well aesthetically. Gently dilating the puncture site with a tenotomy scissors (Fig. 7) allows passage of up to 4-mm-diameter cannulas with an acceptably small closure.

Special consideration is given to tumescent infiltration in the awake patient to ensure that adequate analgesia is achieved without causing undue pain, which is directly correlated to the speed with which the fluid is injected. The extra time given for the awake patient to be infiltrated is worthwhile as the

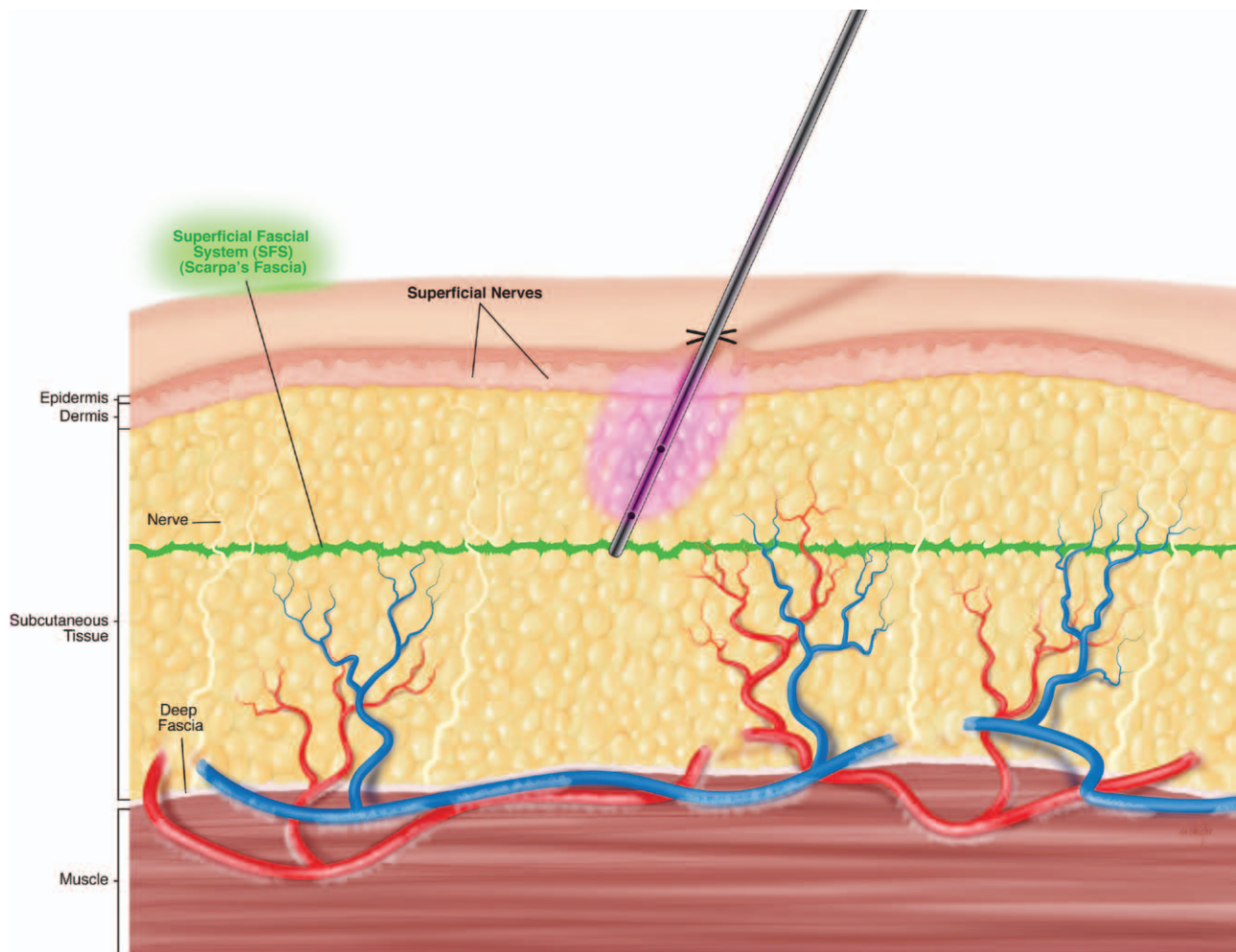


Fig. 8. Step 4: A 14- to 18-gauge Wells-Johnson infiltration cannula is introduced into the intermediate subcutaneous fat space until the SFS is reached. The cannula is then advanced through the SFS with a palpable “pop” to reach the deep subcutaneous fat space. SFS, superficial fascial system.

patient feels minimal discomfort, the lidocaine has a chance to give better analgesia, and the epinephrine has more time to maximize vasoconstriction.

Tumescent solution (1000 mg lidocaine with 1.5 mL epinephrine and 10 mL sodium bicarbonate in 1 L of Ringer’s lactate) is injected into the deep and intermediate subcutaneous spaces with a 14-gauge Wells-Johnson cannula. The blunt-tipped infiltration cannula is carefully passed through the superficial fascial system, palpable to the surgeon as a gentle “pop” (Figs. 8, 9). Once the deep subcutaneous fat space is fully infiltrated, the lidocaine disperses to the more richly innervated superficial and subdermal layers (Fig. 10). Once this layer is anesthetized, the final, more superficial infiltration of tumescent fluid ensures that the patient has complete analgesia (Fig. 11). The advantage of this technique is that the patient gives real-time feedback to the adequacy of the analgesia. This allows the subsequent

application of energy and aspiration of fat without pain. No patient had a lidocaine load exceeding the recommended maximum of 35 mg lidocaine/kg body weight.

Application of the RF Energy to the Soft Tissues. The RFAL device parameters are set with a cutoff temperature of 38–40°C and a power output of 35 W. The depth wheel is set to 3 or 4 cm depending on the thickness of the tissue treated. Bacitracin ointment is used to minimize friction and protect the access incisions. Sterile ultrasound gel is applied liberally over the treated area to decrease impedance between the 2 electrodes. The RFAL device is typically placed first through the elbow region entry ports and gently moved back and forth while avoiding overtreatment in any one area. The treatment strokes are identical to SAL, and the suction is set to 15 mm Hg. This lower setting allows for gentle extraction of the oils

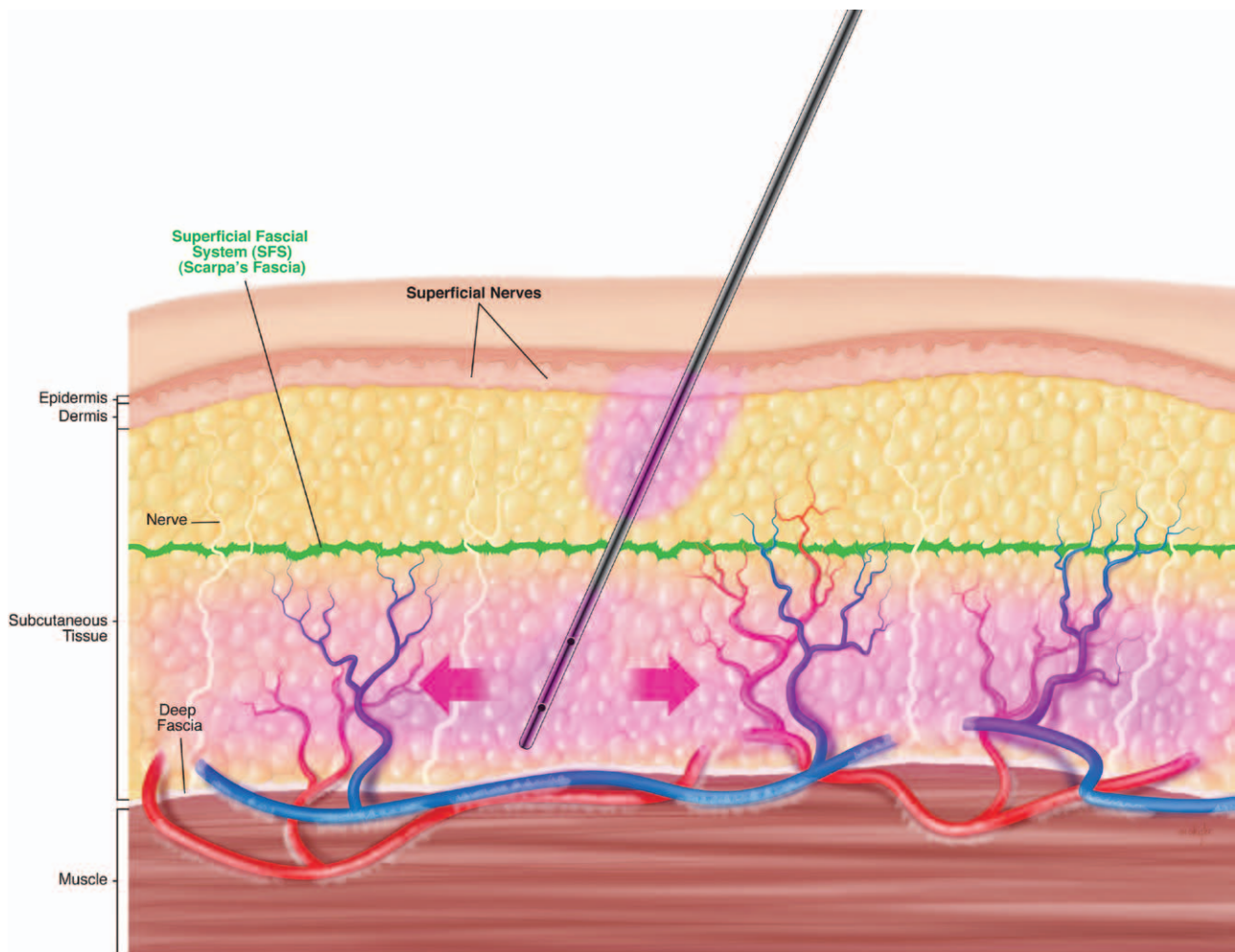


Fig. 9. Step 4 (continued): Once the cannula reaches the deep subcutaneous space below the SFS, infiltration of the tumescent solution is started.

and fluids that are released by the RF energy without significantly changing the contour. This minimizes isolated areas of hardness possibly seen in the first 3 months postoperatively.

As the temperature approaches 35°C, the distance between the 2 electrodes is narrowed to 2 cm and the more superficial layers are treated to a temperature of 38°C. Once 38–40°C is reached, the area is treated for 1 minute at that goal temperature with the endpoint of uniform heating. In addition, we used an infrared camera to independently corroborate the reading of the external electrode and found it to be within 1°C.

Two safety features of the device are controlled energy delivery and the previously mentioned external temperature sensor and cutoff.^{8,10} Real-time temperature monitoring shuts off the RF energy delivery at the temperature maximum. The majority of the energy is directed to the proximal one-third of the arm that corresponds to the area of greatest lax-

ity in most patients. Once the target temperature is reached and the heat is uniformly applied, the RF portion of the operation is concluded. Standard power-assisted liposuction (Microaire, Charlottesville, VA) or SAL is then used for contouring and residual fat removal with 2.7-, 3-, and 4-mm-diameter blunt Mercedes tip cannulas. The incisions are closed with 5-0 nylon sutures removed 1 week post-op. A compression arm garment is then worn for 4 weeks.

Follow-up appointments were made in the office at 1, 4, 12, 26, and 52 weeks. Patients were asked to complete an online survey following their procedure to describe the factors in choosing RFAL, the level of discomfort with the procedure, and their level of satisfaction and time to return to work (Table 1). Also, 3 independent plastic surgeons evaluated photographs of the 6- and 12-month results of the first 20 completed cases. They were asked to grade the improvement in body contouring and the degree of

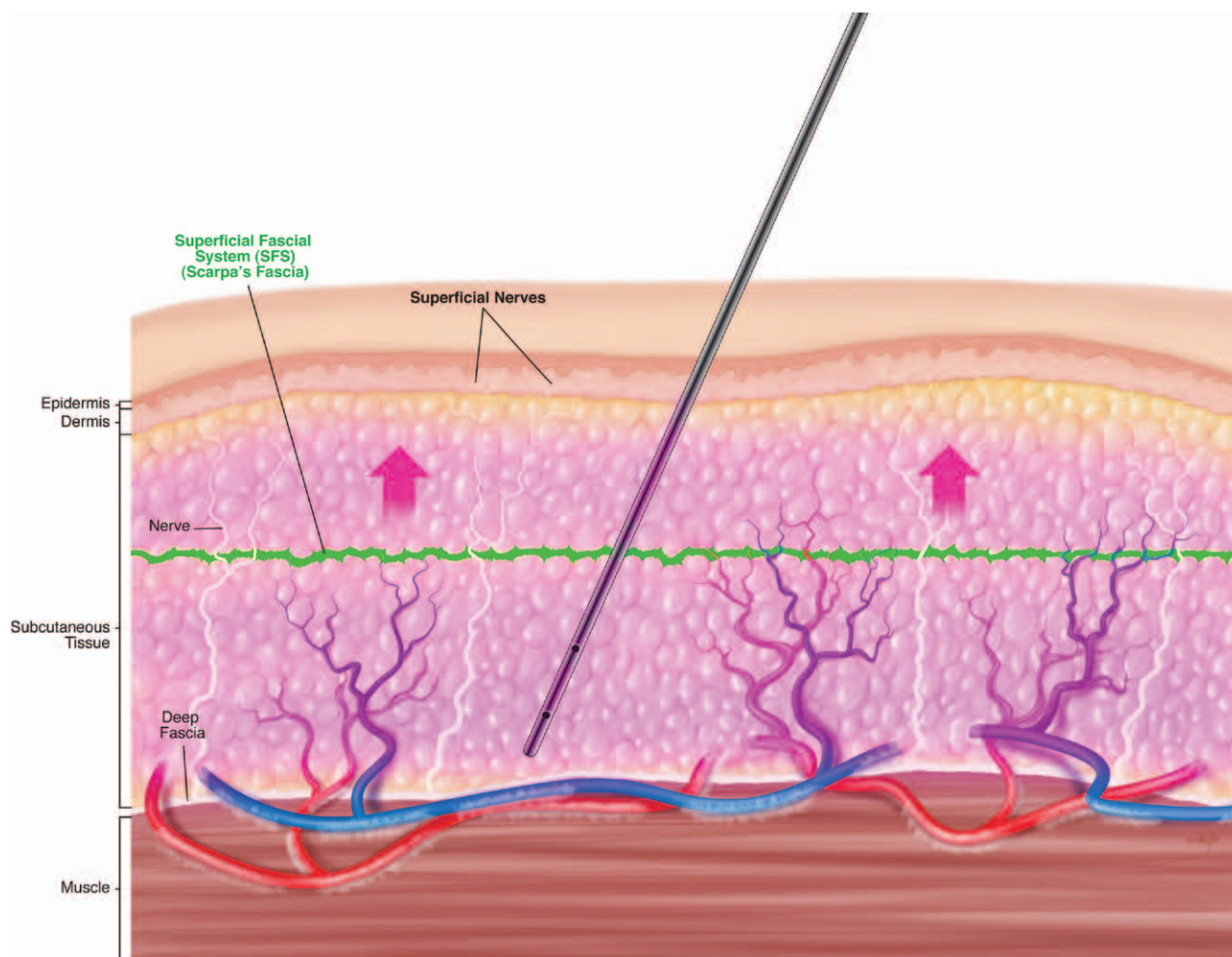


Fig. 10. Step 5: Once the deep subcutaneous fat space is fully infiltrated with tumescent fluid, time is given to allow the richly arborized and nerve-dense superficial and subdermal layers to become anesthetized.

skin tightening using a 4-point scale: 1 = poor, 2 = moderate, 3 = good, and 4 = excellent.

RESULTS

Forty patients underwent RFAL under local anesthesia without any major complications or mortalities. The average age was 40 years and the average body mass index was 31. Average tumescent infiltration volume was 2232 cm³ and average aspirate volume was 1072 cm³ (average fat aspirate volume, 568 cm³). The mean amount of energy applied to both arms was 39.0 kJ delivered at an average setting of 37W with an average temperature maximum of 39°C. Average operating time was 127 minutes. The average lidocaine load was 18.6 mg/kg body weight.

Minor complications occurred in 2 patients (5.4%). A full-thickness burn occurred near the elbow in a 48-year-old woman, which healed with local wound care. One seroma occurred unilaterally in a 50-year-old woman and was treated successfully with

aspiration. No deaths, hospitalizations, or infections occurred and no revisions were performed.

Twenty-seven out of forty patients responded to the questionnaire (67.8%). Regarding the factors in choosing RFAL, 65% cited the ability to have the procedure under local anesthesia, 55% the ability to return to work quickly, and 47% considered the degree of skin tightening important. Forty-five percent of respondents felt no pain on infiltration of the local anesthetic, 35% minimal discomfort, and 15% moderate discomfort, but 5% felt significant discomfort. Regarding discomfort during the application of heat, 39% felt no discomfort, 41% minimal discomfort, 18% moderate discomfort, and 2% significant discomfort. During fat aspiration, 55% felt no discomfort, 32% minimal discomfort, 13% moderate discomfort, and none had significant discomfort.

At 6 months postoperatively, 38% of respondents were extremely satisfied, 19% were very satisfied, 30% were satisfied, and 13% were not satisfied with

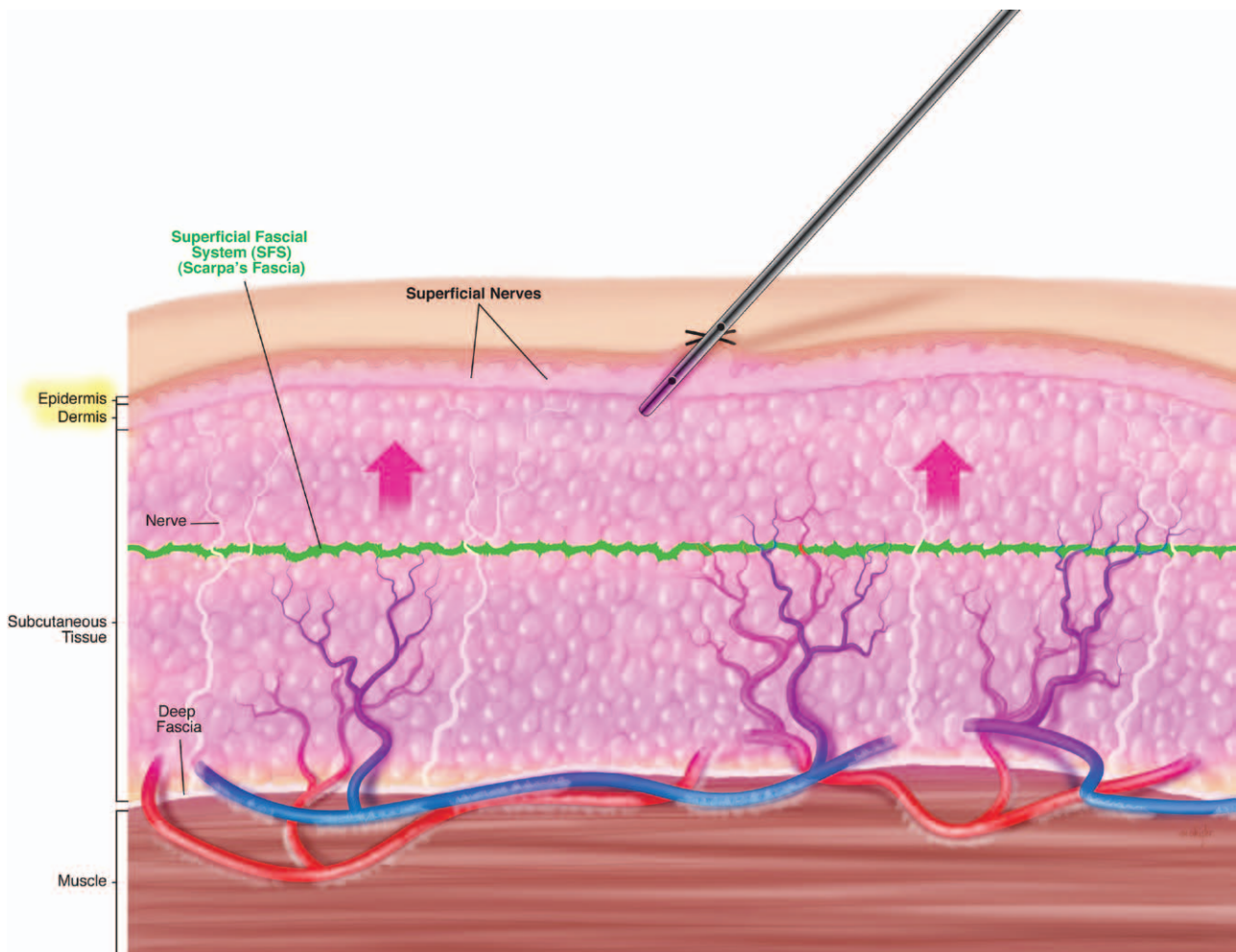


Fig. 11. Step 6: With adequate initial analgesia achieved in the awake patient, the superficial and subdermal layer tumescent infiltration is completed in preparation for the more stimulating RFAL portion of the procedure.

arm contouring. At 6 months post-op, 9% were extremely satisfied, 37% were very satisfied, 39% were satisfied, and 15% were not satisfied with the degree of skin tightening. Eighty-one percent of respondents returned to work within 1–3 days, 17% within 4–6 days, and 2% by 7–9 days. Seventy-three percent said that they would definitely recommend, 19% probably would recommend, and 8% would not likely recommend the procedure.

The 3 independent plastic surgeons' evaluations of the preoperative and postoperative photographs indicated that the improvement in arm contouring was found to be 8% excellent, 72% good, 18% moderate, and 2% poor. They determined the degree of skin tightening to be 11% excellent, 46% good, 38% moderate, and 5% poor.

DISCUSSION

Patients are often told that they require a brachioplasty for aesthetic improvement of their arms or are not candidates for traditional liposuction.

Concerns about the length and appearance of a brachioplasty scar often lead patients to seek other alternatives. RFAL may present an alternative, non-excisional procedure for patients with mild to moderate skin laxity. It has been reported that loose skin can be improved through the effect of the RF energy tightening the connection of the skin/fat layer to the underlying fascia and the overlying dermis.¹⁰ It is important to point out that the degree of skin contracture, in our experience, is variable depending on the patient's Fitzpatrick skin type. In general, patients with a thicker dermis respond better to SAL regardless of energy application. All patients included in this study were counseled that there was a possibility that they may require a form of a brachioplasty in the future.

We believe that arm contouring under local anesthesia is a viable alternative to traditional forms of anesthesia with several advantages in appropriately selected patients. In the patient surveys, 81% returned to work within 1–3 days of the procedure

Table 1. Patient Questionnaire and Answers

1.	What were the most important factors in your decision to have RFAL of the arms (may choose more than one response)?
	– ability to have the procedure under local anesthesia (awake)
	– ability to return to work quickly
	– the degree of skin tightening with the RFAL (BodyTite)
2.	What was your level of discomfort during the injection of local anesthesia?
	– no discomfort
	– minimal discomfort
	– moderate discomfort
	– significant discomfort
3.	What was your level of discomfort during the application of heat with the RFAL (BodyTite) device?
	– no discomfort
	– minimal discomfort
	– moderate discomfort
	– significant discomfort
4.	What was your level of discomfort during the fat aspiration portion of the procedure?
	– no discomfort
	– minimal discomfort
	– moderate discomfort
	– significant discomfort
5.	What was your level of satisfaction with the arm-contouring result at 6 mo after the procedure?
	– extremely satisfied
	– very satisfied
	– satisfied
	– not satisfied
6.	What was your level of satisfaction with the degree of skin tightening 6 mo after the procedure?
	– extremely satisfied
	– very satisfied
	– satisfied
	– not satisfied
7.	How soon did you return to work after the procedure?
	– same day
	– 1–3 d
	– 4–6 d
	– 7–9 d
	– over 9 d
8.	Would you recommend the procedure to someone else?
	– definitely
	– probably
	– not likely

and 55% factored the short recovery time in deciding on the procedure. The ability to perform the operation awake was cited in nearly two-thirds (65%) of those surveyed. Regarding the procedure, the majority of patients had either minimal or no pain in the tumescent phase (80%), the application of heat phase (80%), or fat aspiration phase (87%) of the operation. From the surgeon's standpoint, there was no difference in the technique of energy application or fat removal in this series of local anesthesia patients and patients who had RFAL under traditional anesthesia

We utilized a third-party plastic surgeon survey to assess subjective changes in arm contouring following RFAL at 1 year post-op as compared to the preoperative images. Regarding improvement in arm contour, 98% of the surgeons stated moderate, good, or excellent improvement. Ninety-five percent stated that the skin tightening aspect was moderate, good, or excellent.

We realize that a major limitation of the study besides the subjective nature of the surveys is the lack

of a control where there was no RF energy component to the arm contouring operation. Both arms were treated with the identical procedure. Future studies where a comparison can be made with and without RF energy are warranted to determine its efficacy. The focus of this study is to demonstrate a technique under local anesthesia utilizing RF energy and to establish the safety parameters.

Caution needs to be exercised to avoid thermal injury and over resection. Sterile ice may be necessary to cool areas of erythema on the skin ("hot spots") that can result in blistering and full-thickness burns. Knowing the exact position of the internal electrode and keeping the tip deep is integral to avoiding "end hits." Regarding the possibility of port site burns and end hits, the development of a Teflon sheath over the probe and the tip of the catheter has decreased the risk of burn. With careful consideration of the anatomy with accurate markings and attention to uniform heating of the tissues, these risks are mitigated. Further, these potential complications are reduced with temperature monitoring, experience,

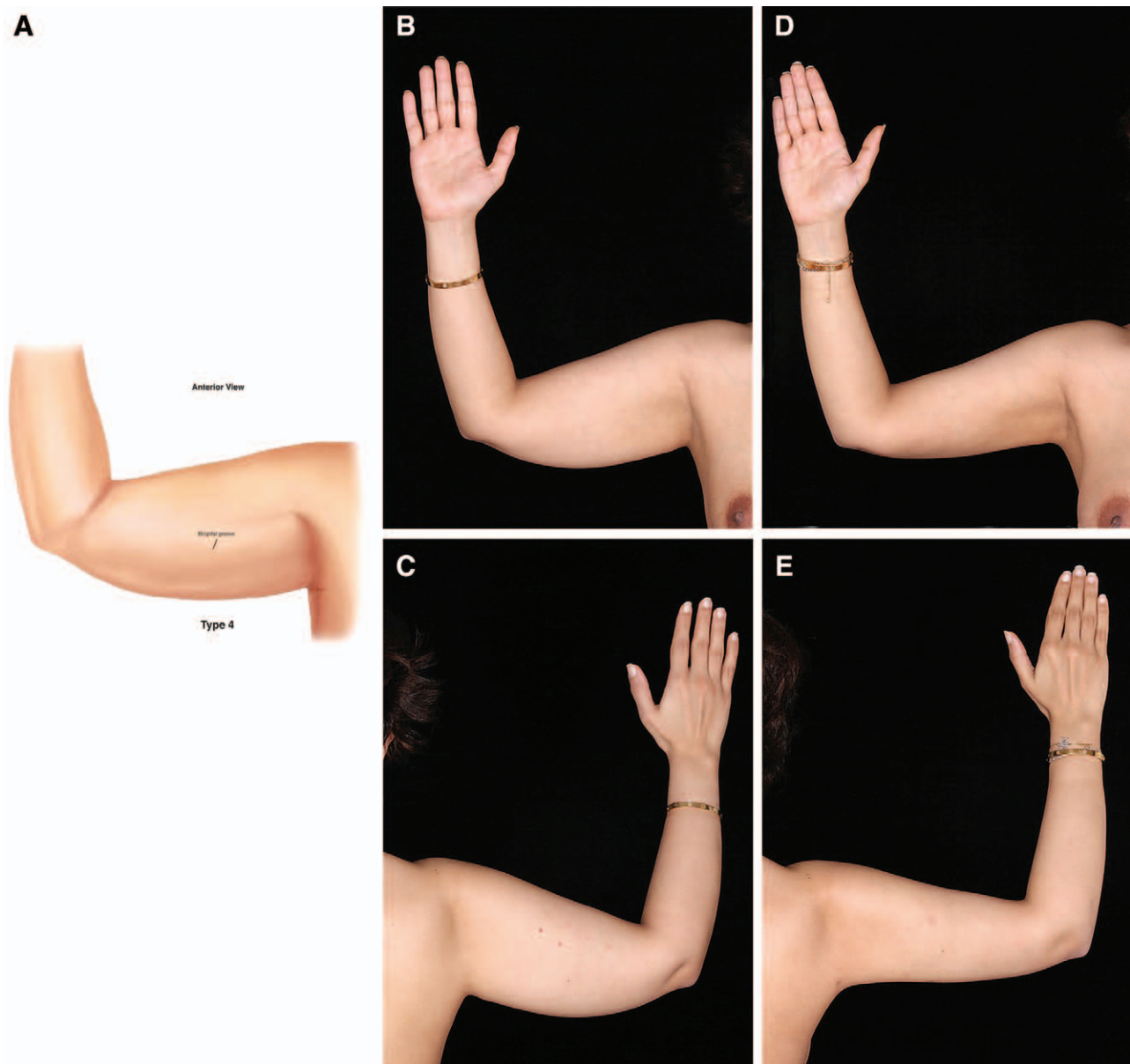


Fig. 12. Idealized image (A) of an anterior view of the right arm preoperatively. Clinical correlates of a 40-year-old woman shown preoperatively with an anterior view (B) and posterior view (C). Following 700mL aspiration with radiofrequency power set at 35 watts, temperature maximum of 38°C and 20.3 kJ total energy delivered, 12-month results shown anteriorly (D) and posteriorly (E).

and modifications to the equipment such as the Teflon-coated tip. The cases complicated with a burn and seroma, respectively, were successfully treated with local care.

CONCLUSION

Arm contouring in patients with excess fat and skin laxity has traditionally been achieved with brachioplasty and the resulting extensive incision and scar. Techniques such as aggressive subdermal liposuction⁴ and energy-assisted liposuction modalities have been reported to result in better skin retraction following

SAL and an improvement in the arm aesthetic.^{2,6,10} RFAL represents a novel technique utilizing electromagnetic radiation to cause contraction of the soft tissue matrix.^{6,10} For patients who are candidates for RFAL (Fig. 12), the operation may be performed under local anesthesia with a focused approach to minimize complications.⁸ Technical considerations include identifying the DFP, TMM, and anatomic zones of the triceps in the operative plan to obtain reproducible results. Future studies where an objective assessment or comparison can be made between RFAL treated areas and traditional SAL would ideally

provide quantitative and qualitative data to support or refute use of energy-assisted modalities in body contouring.

Christopher Chia, MD.

BodySculpt Corporation
128 Central Park South
New York, NY 10019

E-mail: christophertchia@yahoo.com

REFERENCES

1. Gilliland MD, Lyos AT. CAST liposuction of the arm improves aesthetic results. *Aesthetic Plast Surg.* 1997;21:225–229.
2. Rohrich RJ, Smith PD, Marcantonio DR, et al. The zones of adherence: role in minimizing and preventing contour deformities in liposuction. *Plast Reconstr Surg.* 2001;107:1562–1569.
3. El Khatib HA. Classification of brachial ptosis: strategy for treatment. *Plast Reconstr Surg.* 2007;119:1337–1342.
4. Gasperoni C, Salgarello M. Rationale of subdermal superficial liposuction related to the anatomy of subcutaneous fat and the superficial fascial system. *Aesthetic Plast Surg.* 1995;19:13–20.
5. Gasperoni C, Salgarello M, Emiliozzi P, et al. Subdermal liposuction. *Aesthetic Plast Surg.* 1990;14:137–142.
6. Blugerman G, Paul MD, Schavelzon D, et al. Radiofrequency assisted liposuction (RFAL). In: Serdev N. ed. *Advanced Techniques in Liposuction and Fat Transfer.* In Tech; 2011:5–134.
7. Appelt EA, Janis JE, Rohrich RJ. An algorithmic approach to upper arm contouring. *Plast Reconstr Surg.* 2006;118:237–246.
8. Theodorou SJ, Paresi RJ, Chia CT. Radiofrequency-assisted liposuction device for body contouring: 97 patients under local anesthesia. *Aesthetic Plast Surg.* 2012;36:767–779.
9. Poland GA, Borrud A, Jacobson RM, et al. Determination of deltoid fat pad thickness. Implications for needle length in adult immunization. *JAMA* 1997;277:1709–1711.
10. Duncan DI. Improving outcomes in upper arm liposuction: adding radiofrequency-assisted liposuction to induce skin contraction. *Aesthet Surg J.* 2012;32:84–95.
11. Teimourian B, Malekzadeh S. Rejuvenation of the upper arm. *Plast Reconstr Surg.* 1998;102:545–551; discussion 552–553.